Photodynamic Therapy 135

Harvey Lui and Sunil Kalia

Chapter Contents

History and Development 2379
Photodynamic Therapy (PDT) – Photochemistry, Photobiology, and Mechanism of Action 2379
Components of PDT 2382
Dermatologic Applications 2384
Adverse Effects and Complications of PDT 2386
Practice and Techniques 2388
Future Directions 2388

Synonym: ■ Photoradiation therapy

Key features

- Photodynamic therapy (PDT) is an established, light-based therapeutic option for actinic keratoses (AKs) and superficial keratinocyte cancers, with an expanding range of applications including acne, photoaging, cutaneous infections, and vascular anomalies
- The photodynamic effect is due to photochemical reactions that generate singlet oxygen and it requires three components: photosensitizing molecules, photoactivating wavelengths of light, and tissue oxygen
- Singlet oxygen is highly reactive and initiates a series of cellular and tissue reactions that culminate in necrosis, apoptosis, and/or antimicrobial effects; host immunologic responses to singlet oxygen-altered tissue may also contribute to the overall clinical effect
- For cutaneous indications, the current standard technique is topical application of pro-photosensitizers (e.g. aminolevulinic acid and its derivatives) that are metabolized *in situ*, i.e. within the skin, to photoactive protoporphyrin IX
- Non-coherent artificial light (blue or red), daylight, or other light sources can be used to illuminate the skin and energize the photosensitizer

INTRODUCTION

Photodynamic therapy (PDT) requires the sequential administration of a photosensitizing agent that is then activated by light in order to generate singlet oxygen within biologic tissues (Fig. 135.1). Singlet oxygen is a highly reactive form of oxygen that can induce cellular necrosis and/or apoptosis while modulating a variety of biologic processes. During the latter part of the twentieth century, PDT was synonymous with the use of *systemic* photosensitizers in combination with red *laser* light to treat cancers. However, in dermatology, the practice of PDT has evolved into applying a *topical* photosensitizer precursor locally to the skin and then illuminating the treatment site(s) with artificial visible light or natural daylight.

HISTORY AND DEVELOPMENT

The photodynamic effect was originally studied in the early 1900s by a medical student who noted that cultures of *Paramecium* would die only if exposed to both an organic dye (acridine) and visible light. His professor discovered the oxygen-dependence of this effect and coined the term "photodynamic action" to describe the phenomenon. In humans, hematoporphyrin was subsequently shown by Meyer Betz to induce profound and persistent generalized photosensitivity, including when he self-injected this agent. In addition to its fluorescent properties when illuminated with a Wood's lamp, hematoporphyrin was shown to localize to neoplastic tissue and then induce tumor involution when exposed to visible light.

The modern era of clinical PDT began in the 1970s when Dougherty and colleagues combined systemically administered *hematoporphyrin derivative* with visible light to treat cutaneous and subcutaneous malignancies in humans; they also confirmed the role of singlet oxygen[1]. With the advent of lasers and fiberoptic endoscopes, the use of PDT was extended to carcinomas of the lung, bladder, and esophagus. Hematoporphyrin derivative and its subsequent porphyrin-based congeners require intravenous administration, and they induce marked generalized cutaneous photosensitivity that can last for days to weeks, necessitating strict avoidance of outdoor and bright indoor light.

Because they are relatively large molecules, porphyrins are poorly absorbed through the skin. The key breakthrough in developing PDT as a practical dermatologic therapeutic modality can be attributed to the Canadian team of Kennedy and Pottier. In the 1980s, they noted that the topical application of a naturally occurring porphyrin precursor, 5-aminolevulinic acid (ALA), as a prodrug could photosensitize the skin by inducing *local intracutaneous* production of protoporphyrin IX (PpIX; see Fig. 135.1). Their successful treatment of keratinocyte cancers[2] using topical ALA plus broadband red light abrogated the two major disadvantages associated with the use of systemic porphyrin photosensitizers (see above).

The elegance of using topical ALA for PDT lies in how it takes advantage of the endogenous porphyrin biosynthetic pathway (which is present in all nucleated cells) to generate PpIX from ALA. The simplicity of this approach greatly facilitated clinical PDT research, culminating in the FDA approval of topical ALA plus blue fluorescent light for the treatment of actinic keratoses (AKs) in 1999. Five years later, topical methyl aminolevulinate (mALA), an esterified derivative of ALA, in combination with red light-emitting diode (LED) light was approved in several countries for dermatologic PDT. It was subsequently shown that natural daylight could safely and effectively activate ALA for skin-based PDT[3].

PDT – PHOTOCHEMISTRY, PHOTOBIOLOGY, AND MECHANISM OF ACTION

PDT is somewhat analogous to PUVA (psoralen plus UVA light) therapy to the extent that both treatment modalities involve the administration of photosensitizers followed by exposure to specific wavelengths of light. Mechanistically, they involve exogenously derived photosensitizers that transfer photon energy from light to drive specific photochemical reactions within the skin. Nevertheless, there are important differences between PDT and PUVA (Table 135.1), the most fundamental of which is that, by definition, PDT generates singlet oxygen, which in turn is biologically active.

PDT Photochemistry

The transduction of energy from light to tissue can be illustrated diagrammatically by considering the resting and excited states of the molecules involved in photochemical reactions (Fig. 135.2). The photosensitizer is present within the target tissue in its ground, lower-energy resting state. Its efficiency as a chromophore for absorbing light energy

Downloaded for Anonymous User (n/a) at Egyptian Knowledge Bank from ClinicalKey.com by Elsevier on March 10, 2024. For personal use only. No other uses without permission. Copyright ©2024. Elsevier Inc. All rights reserved.

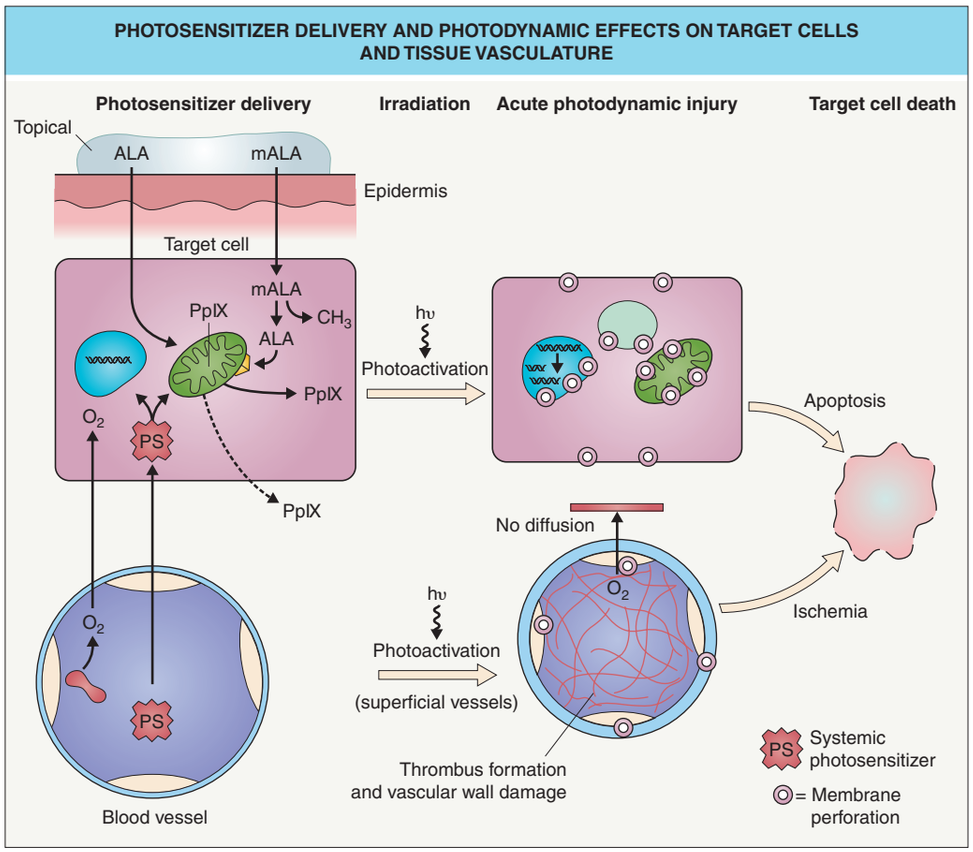

Fig. 135.1 Photosensitizer delivery and photodynamic effects on target cells and tissue vasculature. Topical photosensitizers 5-aminolevulinic acid (ALA) and methyl aminolevulinate (methyl-esterified ALA; mALA) diffuse through the stratum corneum into target epithelial cells; if systemic photosensitizers are used, they arrive through the bloodstream. Oxygen is delivered via erythrocyte circulation. ALA derived from any source is converted to protoporphyrin IX (PpIX) within mitochondria. PpIX then leaks from the mitochondria to other cellular structures. After there has been sufficient time for photosensitizer partitioning to subcellular structures, target tissue is irradiated with photoactivating light. During acute photodynamic injury, plasma and nuclear membranes lose integrity. Acute photodynamic injury within cutaneous endothelial cells leads to thrombus formation and vascular collapse. Target cell and tissue oxygen delivery cease. Both direct apoptosis and ischemic necrosis contribute to irreversible target cell injury and death.

PHOTODYNAMIC THERAPY VERSUS PUVA THERAPY		
Features	**PDT**	**PUVA**
Routes of administration of photosensitizer	Topical Systemic (IV)	Topical Systemic (PO)
Photosensitizer	ALA or mALA (as prodrugs)	8-methoxypsoralen
Active form of photosensitizer	PpIX	8-methoxypsoralen
Photosensitizer activation	Visible light	Ultraviolet A
Photochemical reaction	Type II: converts O_2 to singlet O_2	Type I: covalent adducts between psoralen and DNA; non-oxygen-dependent
Relationship with skin cancer	Treats keratinocyte carcinomas	Carcinogenic
Effects of long-term use	Generally safe, can be used to treat photoaging	Skin cancer, photoaging

Table 135.1 Photodynamic therapy (PDT) versus PUVA (psoralen plus UVA light) therapy. ALA, 5-aminolevulinic acid; IV, intravenously; mALA, methyl aminolevulinate; PO, orally; PpIX, protoporphyrin IX.

is related to its absorption spectrum (Fig. 135.3). If light of an appropriate wavelength reaches the photosensitizer within tissue, photon absorption occurs and the photosensitizer is excited to a higher-energy "singlet" state. This excited singlet is short-lived, lasting nanoseconds, and then undergoes intersystem crossing to a more stable "triplet" state, which has a lifetime on the order of microseconds. The "triplet" photosensitizer can in turn transfer its stored energy to molecular oxygen, yielding singlet oxygen ($^1O_2$), and, as a result, returns to its resting ground state. Photochemical reactions that are mediated by oxygen are referred to as type II photochemical or photosensitized reactions. The singlet oxygen thus generated reacts with a variety of cellular biomolecules, including lipids, proteins, and nucleic acids.

Singlet oxygen is by no means the only active intermediate generated by the excited triplet photosensitizer; a variety of additional reactive oxygen species are also generated from molecular oxygen and undoubtedly contribute to the overall biologic effect. Being highly reactive, singlet oxygen and its related oxygen species can also chemically inactivate the photosensitizer itself by a process known as *photobleaching*, which also destroys its fluorescence properties (Fig. 135.4). This is one way by which the light exposure during PDT automatically self-limits or shuts down the overall process.

Light within the visible spectrum is typically used for PDT. This is because ultraviolet light is carcinogenic and has limited tissue penetration, while infrared radiation (>850 nm) has minimal absorption by ALA.

When PDT photosensitizers are excited to their singlet states following light absorption, they can alternatively return to their ground state via the emission of photons (see Fig. 135.2). This "re-emission" of light by the photosensitizer is termed fluorescence and the latter property permits, with Wood's lamp illumination, direct visualization of photosensitizer accumulation within tissue as well as its subsequent depletion as a result of photobleaching following therapeutic light exposure (see Fig. 135.4).

Photobiologic Mechanisms of Action

Although the precise and most relevant molecular sequence of reactions initiated by singlet oxygen has not been determined, oxidative damage (including to cellular membranes) is known to trigger cellular injury and apoptosis. For a given PDT clinical effect or indication, the specific mechanism of action depends on the target tissue, the photosensitizer and its delivery route, subcellular photosensitizer localization, and the overall drug–light dose delivered. For example, when topical ALA is applied to an epidermal neoplasm such as a superficial basal cell carcinoma (BCC), PpIX accumulates within the tumor cells themselves, with direct cytotoxicity upon light activation (see Fig. 135.1). In contrast, systemic photosensitizers are known to preferentially localize to the vascular bed of tumors. Light activation then leads to vascular collapse and ischemic tumor necrosis.

Downloaded for Anonymous User (n/a) at Egyptian Knowledge Bank from ClinicalKey.com by Elsevier on March 10, 2024. For personal use only. No other uses without permission. Copyright ©2024. Elsevier Inc. All rights reserved.

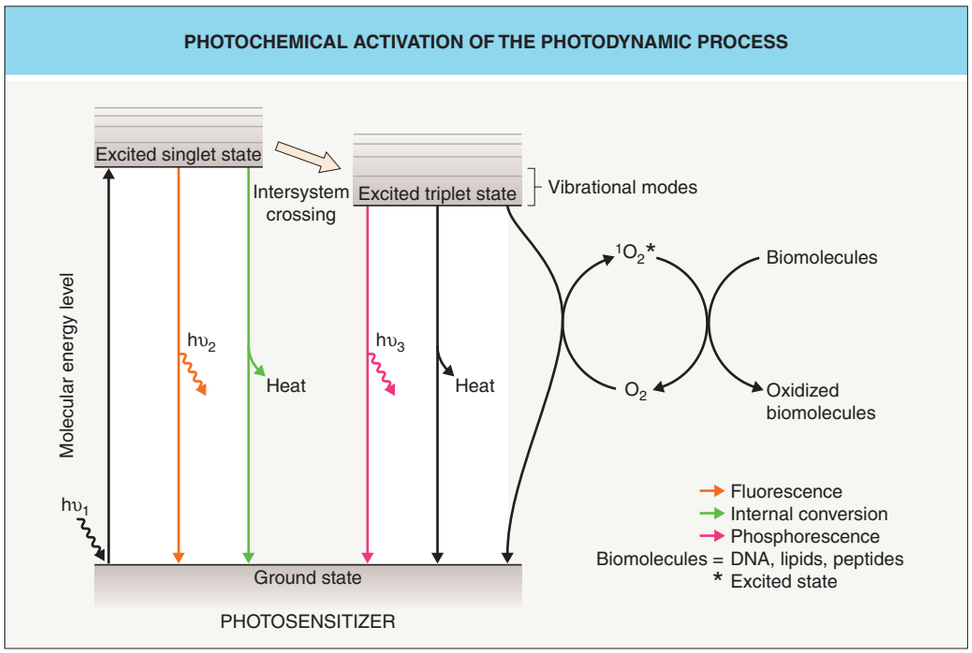

Fig. 135.2 Photochemical activation of the photodynamic process and the generation of reactive singlet oxygen: the Jablonski energy state diagram. The photosensitizer is delivered to or generated within the target tissue in its ground, lower-energy resting state. If light of an appropriate wavelength is used to irradiate the photosensitizer within tissue, photon absorption occurs and the photosensitizer is excited to a higher-energy "singlet" state. The excited singlet is short-lived, lasting nanoseconds, and then undergoes intersystem crossing to a more stable "triplet" state which has a lifetime on the order of microseconds. The "triplet" photosensitizer species can transfer its energy to molecular oxygen, yielding singlet oxygen ($^1O_2$) and as a result, returns to its resting ground state. See PDT Photochemistry section for additional details.

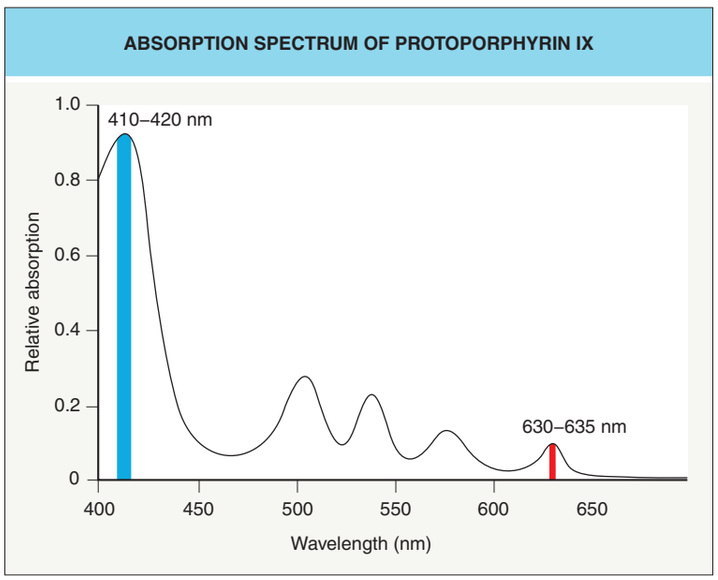

Fig. 135.3 Absorption spectrum of protoporphyrin IX (PpIX). The absorption spectrum depicts the efficiency of absorption of light as a function of wavelength. It reveals the major absorption (photoactivation) peaks of PpIX. Blue (410–420 nm) or red (630 nm) wavelengths are typically used to activate PpIX with artificial light; when daylight is used, the other PpIX absorption peaks are also activated.

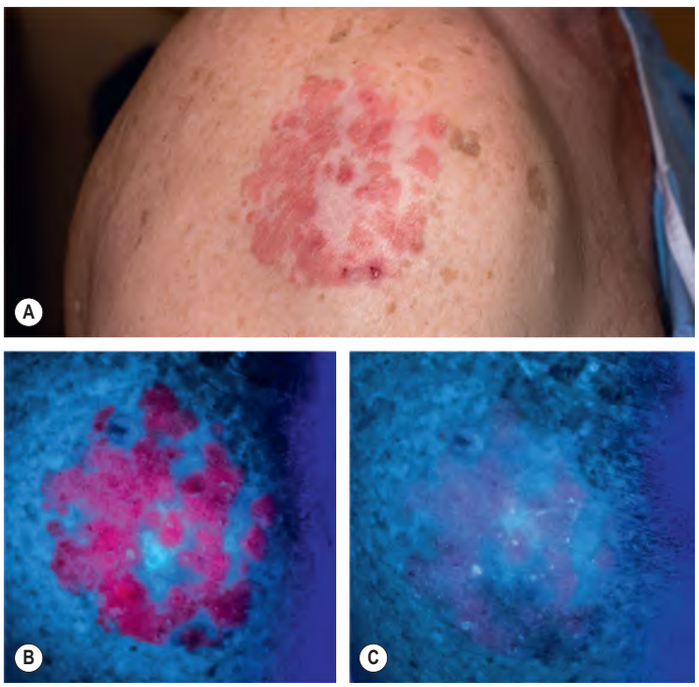

Fig. 135.4 Fluorescence of intratumor protoporphyrin IX (PpIX) when illuminated by a Wood's lamp (365 nm). A Large superficial basal cell carcinoma (BCC) of the shoulder. **B** Following application of topical methyl aminolevulinate (mALA) for 3 hours under occlusion, the BCC demonstrates selective pink-red fluorescence due to accumulation of PpIX. **C** Immediately following exposure to red light from an LED (light-emitting diode), the fluorescence almost disappears due to photobleaching.

At a high drug–light dose combination, greater levels of singlet oxygen are generated during PDT, leading to necrotic tissue damage. With lower levels of drug and/or light, damage is more limited, with predominantly apoptotic changes within cells. Because PDT is oxygen-dependent, larger targeted tumors, which can be relatively hypoxic, may be more resistant to the desired therapeutic effect.

Tissues exposed to PDT can become inflamed as a result of normal host responses to injury as well as activation of specific immunologic reactions. However, the types of immunologic reactions vary depending upon the target and mode of PDT delivery. In animal models of contact hypersensitivity, PDT suppresses local and systemic immune responses in addition to reducing epidermal Langerhans cells[4]. There is also evidence that the photosensitizers used in PDT can target activated T cells[5], providing a rationale for using PDT to treat inflammatory dermatoses or mycosis fungoides. Microbes, including viruses, bacteria, fungi and parasites, may be susceptible to singlet oxygen, and there are clinical studies attesting to the potential utility of PDT in the treatment of skin infections.

PDT Selectivity

PDT was initially conceived and developed as a method for targeted tumor destruction. Several findings help to explain this selectivity (Table 135.2). In neoplasms, where cellular metabolism is higher than normal, local factors such as enhanced perfusion, vascular and lymphatic hyperpermeability, pH, and lipoprotein receptors on target cells may lead to preferential accumulation and retention of photosensitizers within the tumor. For topical PDT, the specific site of drug application is set by the physician, thereby delimiting the area of photosensitization and treatment. Inherent differences in the permeability of skin lesions such as BCCs and AKs facilitate the selective uptake of topical ALA-like prodrugs into diseased skin.

Downloaded for Anonymous User (n/a) at Egyptian Knowledge Bank from ClinicalKey.com by Elsevier on March 10, 2024. For personal use only. No other uses without permission. Copyright ©2024. Elsevier Inc. All rights reserved.

THERAPEUTIC SELECTIVITY DURING PHOTODYNAMIC THERAPY	
Photosensitizer effects	**Light effects**
• Selective photosensitizer retention • Selective photosensitizer biodistribution and uptake • Ability to confine the area of topical photosensitizer application to lesion(s) • Incubation time of topical photosensitzer	• Spatial confinement of light exposure to the target area • Wavelength dependence for light penetration into skin • Photobleaching of photosensitizer

Table 135.2 Therapeutic selectivity during photodynamic therapy (PDT).

Selectivity is also achieved by determining the manner in which PDT light is delivered (see Table 135.2). This involves aiming the activation light at just the specific skin target (plus a limited margin of adjacent normal-appearing skin). Most clinical photosensitizers, and porphyrins in particular, exhibit multiple absorption maxima across the visible spectrum (see Fig. 135.3). Because light penetration within tissue is wavelength-dependent, the use of shorter wavelengths, i.e. blue light, will primarily limit the PDT effect to the epidermis, whereas red light will induce deeper biologic and clinical effects.

Photosensitizer localization within the skin can be readily visualized because PDT photosensitizers usually have high fluorescence quantum yields that are apparent with Wood's light examination (see Fig. 135.4). However, the intensity of this fluorescence does not necessarily correlate with the ensuing PDT reaction or ultimate clinical outcome. Following the therapeutic light exposure stage, the phenomenon of photobleaching can be confirmed visually by the absence or marked reduction of fluorescence.

Advantages and Limitations of PDT

Advantages of PDT include its relative conceptual simplicity as well as the accessibility of the skin to direct application of photosensitizing drugs and activating light. PDT photosensitizers typically have minimal dark toxicity (i.e. negligible toxicity in the absence of light) and are therefore relatively safe. PDT can also be used in patients with a variety of comorbidities, including those who are anticoagulated. PDT treatments can be repeated and there are minimal long-term side effects. Additionally, it has the advantage of being a physician-supervised therapy, which limits the effects of low adherence as can be the case with at-home topical treatments.

Nonetheless, PDT is far from a perfect therapeutic modality as it has inherent limitations. Topical photosensitization is limited by drug penetration into the epidermis and dermis, while the depth of penetration of visible light is also limited when exposure is via surface illumination. Thus, PDT is primarily useful for treating cutaneous tumors or diseases that are relatively superficial.

The multiplicity of potential drug and light dose combinations and permutations makes it complicated to determine the optimal conditions necessary for effective and safe PDT. Moreover, the literature is replete with a wide array of different reported parameters, making it difficult to standardize treatment regimens and compare clinical efficacy, even for the same indication. The commercially recommended treatment parameters are based on strict clinical trial protocols and do not provide much flexibility in terms of dosing. From the patient perspective, intraoperative local pain at the site of light exposure can be intense and even intolerable, and for many patients this represents the most significant disincentive for repeat treatments. Commercially available PDT systems (i.e. photosensitizers and artificial light sources) incur significant cost, thereby posing a practical barrier to accessing a treatment that is fundamentally based on a naturally occurring compound combined with visible light. Natural daylight activation of photosensitizers can partially circumvent the costs, pain, and apparent complexity of administering PDT.

COMPONENTS OF PDT

A range of photosensitizers have been developed and evaluated along with a multiplicity of different light sources and delivery systems (Table 135.3). The two basic pro-photosensitizers that are utilized are ALA and mALA. They were originally used with either artificial blue or red light devices. Additional light sources have been adopted and include natural daylight and investigative garments that incorporate low irradiance light-emitting diodes and are placed over the skin.

Photosensitizers

Although topical and systemic photosensitizers based on the full porphyrin structure have been developed and evaluated, to date none have become practical, either on a clinical or commercial level, for dermatologic use. Thus, for practical purposes, topical PDT relies primarily on the "ALA prodrug" approach.

ALA and mALA represent topical prodrugs that are converted within the skin into PpIX. A familiarity with porphyrinogenesis in mammalians aids in understanding the pharmacology of ALA and its congeners. ALA (5-aminolevulinic acid, δ-aminolevulinic acid) is synthesized in all nucleated cells, and it is an intermediate compound in the heme biosynthetic pathway (see Fig. 49.1); ALA synthase catalyzes the formation of ALA from succinyl-CoA and glycine. The latter reaction represents the rate-limiting step in this pathway and is inhibited by heme. When pharmacologic quantities of ALA are supplied to cells as in PDT, this regulatory step is bypassed, leading to an intracellular accumulation of PpIX, which is photodynamically active. Of note, PpIX is synthesized within mitochondria (see Fig. 135.1) and then diffuses to cellular membrane systems such as the endoplasmic reticulum and the plasma membrane.

Unlike fully formed porphyrin molecules that are relatively large, ALA is small and readily crosses the cutaneous permeability barrier via active transport mechanisms. Within the skin, the absorbed ALA induces porphyrinogenesis, thereby inducing "porphyria" at the cellular level. In some PDT applications, the skin is first prepared by gentle curettage to remove excess surface scale and crust or to remove the stratum corneum; this preparatory step can promote topical drug absorption. Within the skin, PpIX accumulates in the epidermis and sebaceous glands due to its lipophilicity.

The carboxyl moiety of ALA can be esterified by a variety of side chains, the simplest of which results in mALA. Substituted ALA congeners are absorbed into the skin by passive and active mechanisms different from those of ALA. Upon their uptake into cells, these substituents are hydrolyzed to yield free ALA (see Fig. 135.1). Both ALA and mALA are considered prodrugs or pro-photosensitizers since the skin cells themselves generate the active photosensitizer PpIX following application of these exogenous compounds.

ALA has been compounded in a variety of different vehicles for topical application and, in North America, it is currently commercially available in 10% and 20% preparations. The FDA-approved indication for ALA is treatment of AKs, although multiple off-label uses have been explored and described (Table 135.4). An incubation time allows ALA to be absorbed and converted to PpIX. When utilizing artificial light with ALA, many clinicians typically use a shorter incubation period of 1–4 hours, instead of the recommended 14–18 hours employed in the original controlled clinical trials. Pretreatment with microneedling or ablative fractional laser therapy can allow for even shorter incubation times while retaining similar efficacy in reducing AKs[6].

Mechanistically, mALA is similar in principle to ALA; it is available in a 16.8% cream formulation that must be refrigerated. The recommendation is to apply mALA for 3–4 hours under occlusion prior to exposure to red light from an LED device. It has been used for multiple different skin diseases, but depending upon the country, the approved indications include treatment of AKs and/or superficial keratinocyte carcinomas (see Table 135.4). Currently, mALA is not commercially available in the US.

Newer ALA formulations have recently been developed, including a nanoemulsion gel and an ALA-impregnated adhesive topical patch, with the latter not requiring pretreatment with curettage (see Table 135.3)[7].

Light Sources

Choosing a light source for PDT depends fundamentally on three considerations. First, the spectral output of the light should include a waveband that corresponds to one or more of the peaks in the absorption spectrum of the photosensitizer (see Fig. 135.3). Next, the desired depth of effect determines which photosensitizer absorption peak should be chosen. For PpIX, red light activation will provide a deeper clinical effect as compared to blue light. Finally, the surface area to be treated must be considered. For example, while lasers can provide precise irradiation, they may be less practical when treating broader, extensive surfaces.

Downloaded for Anonymous User (n/a) at Egyptian Knowledge Bank from ClinicalKey.com by Elsevier on March 10, 2024. For personal use only. No other uses without permission. Copyright ©2024. Elsevier Inc. All rights reserved.

COMPARISON OF ARTIFICIAL LIGHT-ACTIVATED PDT, DAYLIGHT-ACTIVATED PDT, AND ALTERNATIVE TECHNIQUES FOR PDT			
Feature	**Artificial light-activated PDT**	**Daylight-activated PDT (D-PDT)**	**Technique variations of PDT (off-label)**
Lesion preparation	• Curettage	• Application of sunscreen (15 min prior) • Curettage	• Topical keratolytics (e.g. retinoids, salicylic acid, α-hydroxy acids) • Tape stripping • Microdermabrasion • Fractional CO_2 laser • Fractional Er:YAG laser • Microneedling • Elevation of skin temperature
Drug delivery	• Topical	• Topical	• Topical • Intralesional • Intravenous • Iontophoresis • Ultrasound-assisted
Photosensitizer	• ALA 20% hydroalcoholic solution (Levulan®)* • mALA 16.8% cream (Metvixia®)*,†,‡ • ALA 10% gel (Ameluz®)*,† • ALA-impregnated patch (Alacare®)†,‡	• mALA 16.8% cream (Metvixia®) • Use of other photosensitizers for D-PDT is possible but off-label; limited published evidence	• Various other photosensitizers
Incubation time before light exposure	• ALA solution: 1–4 h (FDA-approved for 14–18 h for face and scalp, 3 hours for upper extremities; no occlusion)* • mALA: 3–4 h, under occlusion*,†,‡ • ALA gel: 3 h, under occlusion*,† • ALA patch: 8 mg/4 cm^2 apply plaster for 4 h†,‡	• Maximum 30 min, no occlusion	• Variable
Light activation	• ALA solution: blue fluorescent light (417 nm peak emission, 10 J/cm^2 [Blu-U®])* • mALA: red LED light (630 nm peak emission, 37 J/cm^2 [Aktilite®])*,†,‡ • ALA gel: red LED light (635 nm peak emission, 37 J/cm^2 [BF-RhodoLED®])*,† • 5-ALA patch: red LED light	• Daylight exposure for 2 h†	**Light sources:** • Other LED lamps • Lasers (e.g. copper vapor, KTP, pulsed dye) • Intense pulsed light • Wearable low-irradiance light source (Ambulite®) • Incandescent lamp (e.g. slide projector) • Arc lamp • Metal halide lamp • Fiberoptic probes **Light delivery:** • Fractionated (i.e. repeat) light doses within the same PDT session may enhance the effect
Pain	• Mild to severe (depending on incubation period)	• Minimal to low	• Variable

*FDA-approved; Metvixia® and Aktilite® were approved by the FDA, but are currently unavailable commercially in the US.
†Approved in multiple European countries.
‡Approved in the UK and Australia.

Table 135.3 Comparison of artificial light-activated PDT, daylight-activated PDT, and alternative techniques for PDT. ALA, 5-aminolevulinic acid; BCC, basal cell carcinoma; LED, light-emitting diode; mALA, methyl aminolevulinate.

Artificial light sources (conventional PDT)

The use of artificial lamps can be referred to as "conventional PDT". Light-emitting diodes (LEDs) and blue fluorescent lamps have been the most commonly employed and approved artificial light sources for PDT (see Table 135.3). In general, these commercial devices are relatively simple to use and can be powered by standard electrical outlets.

Off-label light sources have also been used for PDT. Lasers (e.g. copper vapor, KTP, pulsed dye) may be as effective as non-coherent artificial lights for PDT[8]. However, they are significantly more expensive, more complex to operate, and less studied. Intense pulsed light (IPL) has also been used as an artificial light source for PDT[9]. Adhesive light-emitting patches[10] and fabric garments with incorporated lights[11] have been designed to be worn by patients, and because they operate at low irradiances, there may be less pain associated with these devices.

Natural outdoor light (daylight PDT; D-PDT)

Studies have shown that natural outdoor light may be used for "daylight PDT (D-PDT)". Drug activation occurs because this light includes all the appropriate activating wavelengths. The main apprehension with daylight activation is the inability to precisely control the light dose delivered to the skin, with the possibility of phototoxicity from overexposure or lack of efficacy due to underexposure. However, randomized controlled trials have demonstrated both safety and efficacy of daylight-activated PDT (DA-PDT). Specifically, non-inferiority for effective treatment of AKs and superiority in degree of associated pain were demonstrated in a split-face trial of daylight- versus red light-activated PDT[3].

Although not yet FDA-approved, D-PDT has several practical and safety advantages. There is no requirement for a specific topical drug incubation time since patients are typically exposed to outdoor light immediately after drug application. Patient self-exposure to ambient outdoor light eliminates the requirement for staff to operate a specialized device and, perhaps most importantly, the level of PDT-related pain is much reduced with D-PDT. Published measurements of daylight doses in various cities can help clinicians identify months in which there is sufficient outdoor light to effectively administer D-PDT in their locale[12,13]. As a general rule, if the latitude is <45° (as in most of the US, southern Europe, South America, and Australia), PDT can be done year-round depending on weather conditions[14]. At higher latitudes in the northern hemisphere, it might be preferable to avoid daylight PDT from October to April. Of note, direct sunlight exposure to the skin is not necessary for daylight PDT. Lastly, non-mineral, untinted sunscreens applied to provide daylight UV protection do not interfere with the absorption of visible light by PpIX.

Light delivery

Regardless of the specific light source, the PDT light dose is measured and delivered in a manner analogous to conventional phototherapy. The ***irradiance*** of the light source is specified in units of W/cm^2, which represents the power density per unit area. Irradiance depends on the light source itself, and it can vary based on the lamp's age, overall operating conditions, and the distance from the lamp to the skin target. For D-PDT, irradiance is affected by geographic location, season, time

Downloaded for Anonymous User (n/a) at Egyptian Knowledge Bank from ClinicalKey.com by Elsevier on March 10, 2024. For personal use only. No other uses without permission. Copyright ©2024. Elsevier Inc. All rights reserved.

PHOTODYNAMIC THERAPY – DERMATOLOGIC APPLICATIONS	
FDA-approved indications	
Actinic keratoses of the face and scalp (ALA solution/blue light or ALA gel/red light) Actinic keratoses of the upper extremities (ALA solution/blue light)	
Off-label* applications with controlled studies demonstrating efficacy	
Actinic keratoses (including D-PDT and PDT of sites other than the face, scalp, and upper extremities) Superficial basal cell carcinoma Squamous cell carcinoma *in situ* (Bowen disease) Prevention of keratinocyte carcinomas	Acne Photoaging Verrucae vulgares Condylomata acuminata Leishmaniasis
Off-label applications for which PDT is *not* considered first-line therapy	
Actinic cheilitis Porokeratosis Sebaceous hyperplasia Nodular basal cell carcinoma Extramammary Paget disease Cutaneous metastases Capillary malformations (port-wine birthmarks)	Rosacea Psoriasis Hidradenitis suppurativa Necrobiosis lipoidica Chronic ulcers Superficial fungal infections
Diseases for which PDT is *not* generally recommended	
High-risk basal cell carcinoma Invasive squamous cell carcinoma	Melanoma
*Per the FDA.	

Table 135.4 Photodynamic therapy (PDT) – dermatologic applications. ALA, 5-aminolevulinic acid; D-PDT, daylight-activated photodynamic therapy; mALA, methyl aminolevulinate.

of day, cloud coverage, humidity, and air pollutants. The light dose used to activate the photosensitizer is also known as the ***fluence*** and is measured in J/cm^2. The ***exposure time*** in seconds required to deliver a specified fluence can be determined from the formula:

$$\text{exposure time (seconds)} = \frac{\text{fluence (J/cm}^2)}{\text{irradiance (W/cm}^2)}$$

PDT Dosimetry

Although PDT is deceptively simple in concept, there are multiple considerations when determining the appropriate doses of photosensitizer and light. Current clinical PDT dosing guidelines have been determined by systematic as well as semi-empiric clinical investigations; nevertheless, they are based on several basic concepts unique to PDT. The net production of singlet oxygen depends on both the amount of photosensitizer and the fluence of light delivered to the target. A certain degree of reciprocity (i.e. inverse relationship) exists between these two components, in that a high photosensitizer level combined with a low fluence can in theory produce an equivalent amount of singlet oxygen as a low concentration of photosensitizer activated by a high fluence.

Another important limit to the principle of drug–light dose reciprocity relates to the irradiance of the activating light. At very high irradiances, there is significant heat production due to both non-radiative photosensitizer absorption/relaxation and nonspecific light absorption by other tissue chromophores. This leads to photothermal effects superimposed on the PDT process itself. At lower irradiances, however, there is evidence that the pain associated with PDT might be reduced[15]. In D-PDT, the reduced pain may be due to the lower irradiance and longer gradual exposure to natural outdoor light as compared to artificial lamps (i.e. hours versus minutes).

An interesting and useful variation in light delivery is to fractionate the total light dose into a series of two or more separate exposures, each punctuated by defined pauses. The potential net effect of fractionating the light dose is to achieve a greater overall PDT effect without applying more drug[16,17]. Mechanistically, there are several reasons why this can happen. During PDT, molecular oxygen is consumed, and a pause in light exposure allows oxygen to be replenished via vascular reperfusion and diffusion. Likewise, this pause may also allow more PpIX photosensitizer to be synthesized *de novo* from the residual ALA that may still be present within viable skin cells; unlike PpIX, ALA itself does not undergo photobleaching.

Other factors that can influence the PDT effect include the duration of incubation between drug application and light exposure. A longer incubation interval for topical ALA or mALA leads to greater accumulation of active photosensitizer in the skin prior to light exposure. With D-PDT, the incubation period is intentionally minimal since patients are typically instructed to go outdoors immediately after the topical agent is applied. In this way, PpIX is gradually activated as soon as it is synthesized in the skin, which is another reason why there is less overall treatment pain with D-PDT.

DERMATOLOGIC APPLICATIONS

PDT agents can photosensitize neoplastic, inflamed, and vascular tissues, modulate immunologic processes, localize to the pilosebaceous unit, and induce lethal damage to microbes. To date, good-quality clinical evidence outside of cutaneous oncology is limited; for the most part, non-oncologic uses of PDT are off-label or investigational. Dermatologic applications for PDT are summarized in Table 135.4.

Oncologic

PDT is an accepted and approved treatment for AKs. There are also multiple controlled trials on the use of topical PDT for superficial carcinomas such as superficial BCC and Bowen disease (squamous cell carcinoma *in situ*) with licensed approvals varying according to country. PDT is not indicated for cutaneous melanoma.

Based on biophysical considerations alone, AKs can be treated with either blue or red light, whereas red light should be used for superficial keratinocyte carcinomas because of its deeper tissue penetration. Multiple studies have documented that cosmesis following PDT can be superior to that following conventional therapies[18]. PDT may be particularly practical and well suited for patients with multiple synchronous AKs or larger, superficial keratinocyte carcinomas, as well as those with evidence of field cancerization. A single PDT session may be sufficient for AKs, with retreatment if required, whereas at least two separate PDT sessions are usually recommended for the treatment of superficial BCC and Bowen disease.

Actinic keratoses

Clinical trials have demonstrated that up to 90% of face and scalp AKs can be cleared with topical PDT (Fig. 135.5), with a one-year sustained clearance of ~80%[19]. ALA and mALA appear to have similar clearance rates[20]. The PDT clearance rate is superior when compared to cryotherapy, 50% trichloroacetic acid, topical diclofenac, and CO_2 laser[21–24], but less effective than topical 5% 5-fluorouracil; it is comparable to topical imiquimod for AKs on the head[25]. PDT combined with imiquimod is more effective than either treatment alone[26], and fractionation of light exposures is associated with improved outcomes[17].

On acral sites, cryotherapy may perform better than PDT (88% vs 78% clearance in one study)[27], which in turn may clear more lesions than imiquimod (58% vs 37%)[28]. Patients also report higher satisfaction with PDT than with imiquimod[29]. Resistance to PDT may be explained by the hyperkeratotic nature of AKs in acral sites, thus making them more difficult to eradicate due to drug and light penetration issues. Consequently, prior to PDT, gentle curettage debridement of scale is often recommended. Several other methods for lesion preparation to enhance PDT efficacy have been described (see Table 135.3). For hypertrophic AKs, multiple treatment sessions may be required to achieve a satisfactory overall result. PDT can also be used in combination or sequentially with other topical treatments for AKs.

In solid organ transplant recipients, the response rate to PDT appears to be lower than in immunocompetent patients (48% vs 72%)[30]. This supports a role for immune activation as part of the mechanism of action of PDT. That said, possibly due to its major effect being direct cytotoxicity, PDT has been shown to be superior to topical 5-fluorouracil or imiquimod for clearance of AKs in transplant recipients[31].

Daylight treatment of AKs has been studied extensively. In randomized controlled trials, mALA D-PDT for AKs was as effective, less painful, and scored higher for patient satisfaction compared to red LED-activated mALA PDT[3,32]. In general, two hours of daylight exposure are sufficient to deliver an effective light dose throughout the year at latitudes <45° (see above regarding higher latitudes)[14,33]. As expected, mALA D-PDT clears

Downloaded for Anonymous User (n/a) at Egyptian Knowledge Bank from ClinicalKey.com by Elsevier on March 10, 2024. For personal use only. No other uses without permission. Copyright ©2024. Elsevier Inc. All rights reserved.

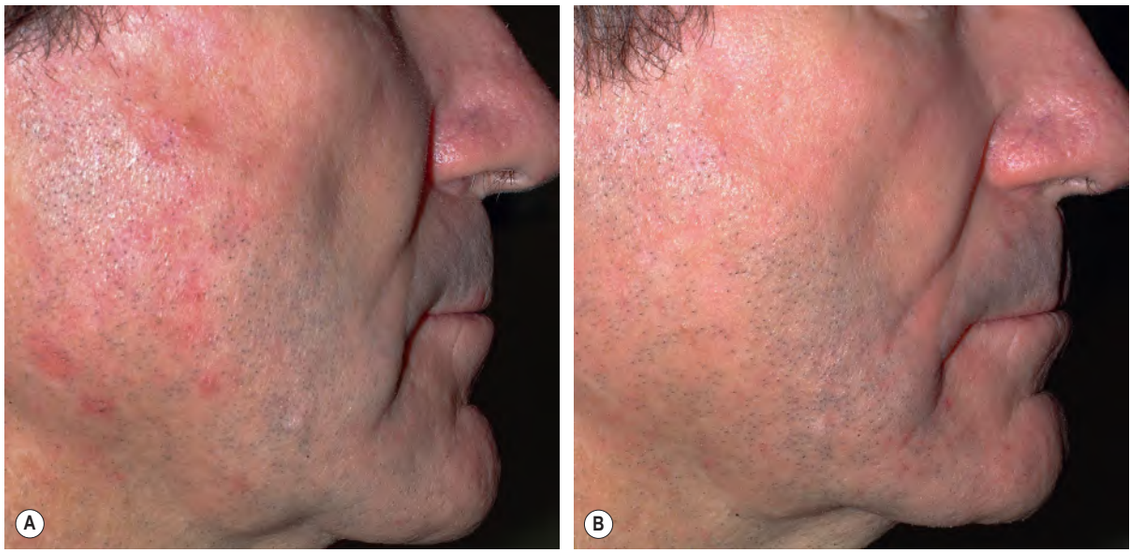

Fig. 135.5 Photodynamic therapy (PDT) of facial actinic keratoses and photoaging. A Pretreatment. **B** Following 3 monthly PDT sessions utilizing topical methyl aminolevulinate (mALA), clearing of actinic keratoses and a smoother, more even skin surface texture and color. *Courtesy Luis Torezan, MD.*

Fig. 135.6 Photodynamic therapy (PDT) of a large superficial basal cell carcinoma (BCC). A Superficial BCC measuring 11.5 by 9 cm on the upper abdomen. **B** Six months following 6 sessions of PDT using topical methyl aminolevulinate (mALA) followed by irradiation with red light from an LED (light-emitting diode), there is complete clinical clearing (closer view).

thin AKs more readily than hypertrophic AKs[34]. D-PDT with either mALA or ALA nanoemulsion gel have been used successfully to treat AKs[35].

Actinic cheilitis represents a useful potential PDT application since alternative treatment approaches such as surgical vermilionectomy or laser vaporization are more complicated and have associated morbidities[36].

Basal cell carcinomas (BCCs)

Superficial BCCs respond well to PDT, with an expected primary clearance rate of 92%–97% at 12 weeks and 9% recurrence rate at 12 months (Fig. 135.6)[37,38]. Although less effective than surgery, PDT has the advantage of improved cosmetic outcome over both surgery and cryotherapy. Longer term follow-up with a two-session protocol found that the 5-year response rate for imiquimod (80%) was superior to either 5-fluorouracil (70%) or PDT (63%) for clearance of superficial BCCs[39]. More than one session of PDT is recommended to treat a given BCC and two separate illuminations per treatment session (fractionation) increases the long-term clearance rate[16].

Nodular BCCs do not appear to be as well suited to PDT in that lower and variable response rates of 35%–90% have been observed[40]. This type of BCC is best treated surgically when possible. Similarly, difficult-to-treat BCCs (e.g. high risk areas of the face, recurrent, sclerosing type) are probably best treated by Mohs micrographic surgery because of the importance of achieving deep margin control. Multiple superficial BCCs arising in the context of cancer-prone genodermatoses such as basal cell nevus syndrome are a good indication for PDT since multiple lesions can be treated during one session and multiple surgeries thereby minimized[41].

D-PDT has also been studied for the treatment of superficial and nodular BCCs, with ~75% of lesions treated with two sessions having a complete response at 12 months[42]. Because daylight activation of photosensitizers may be due predominantly to the superficially penetrating blue wavelengths within natural outdoor light[13], it is not yet known if daylight is a sufficiently effective light source for treating BCCs.

Squamous cell carcinomas (SCCs)

Bowen disease is confined, by definition, to atypical keratinocytes that span the entire epidermis, and is thus eminently within the therapeutic range of PDT. Many PDT experts consider Bowen disease to be an ideal application since PDT can be used to treat multiple lesions as well as large, extensive plaques. A PDT clearance rate for Bowen disease of ~90% can be achieved with a 2-year sustained clearance rate of ~70%[43]. For clearance of Bowen disease, PDT outperforms topical 5-fluorouracil, imiquimod, and cryotherapy[44,45]. Bowen disease of the anogenital region and lower extremity can also be an appropriate target for PDT. In the case of lower extremity Bowen disease, a single session of ablative fractional laser-assisted PDT demonstrated superior long-term efficacy compared to two standard mALA sessions, with a 5-year clearance rate of 85%[46]. In this setting, the fractional laser is not used for photosensitizer activation, but rather for treatment site preparation prior to topical drug application (see Ch. 136). PDT is not recommended for recurrent Bowen disease or microinvasive or invasive SCC[43].

PDT photochemoprevention of AKs and keratinocyte carcinomas

PDT is an effective intervention for managing field cancerization beyond just clearing visible AKs. There is increasing evidence that skin sites treated with topical PDT may develop new lesions at a slower rate, raising the possibility of a photodynamic prevention effect[47]. Photochemoprevention with PDT may prove especially beneficial in reducing the incidence of AKs and SCCs in solid organ transplant recipients, particularly when periodic "maintenance" PDT is performed[48].

Extramammary Paget disease

Treatment of *in situ* extramammary Paget disease is complicated given the difficult anatomic locations of these lesions, the high recurrence rate due to unpredictable subclinical and adnexal extension, and significant

Downloaded for Anonymous User (n/a) at Egyptian Knowledge Bank from ClinicalKey.com by Elsevier on March 10, 2024. For personal use only. No other uses without permission. Copyright ©2024. Elsevier Inc. All rights reserved.

morbidity. Although PDT is a potential treatment that would allow anatomic preservation, variable success has been reported; the absence of conclusive evidence precludes its recommendation as first-line therapy.

Other neoplasms

Because activated and malignant T cells can be selectively sensitized by exogenous ALA, PDT has been used to treat the mycosis fungoides form of cutaneous T cell lymphoma[49]. Patch- or plaque-stage lesions may be more responsive than tumor-stage mycosis fungoides. While PDT's historical roots in dermatology lie in its initial use during the 1970s to treat intracutaneous metastases[1], it is now widely accepted that PDT is far more appropriate for treating superficial carcinomas rather than advanced disease.

Non-Oncologic PDT Applications

Acneiform disorders

Not only did early studies demonstrate that exogenous ALA could induce PpIX formation within the skin, they also noted the preferential accumulation of active photosensitizer and selective phototoxicity within the pilosebaceous unit. In addition, singlet oxygen exerts antibacterial and anti-inflammatory effects. These effects, in addition to antibiotic resistance and the challenges surrounding the use of oral isotretinoin, have provided an impetus to developing PDT regimens for acne. A reduction in inflammatory acne lesions of 60%–70% was reported with both ALA and mALA PDT, with the two photosensitizers producing similar effects. Use of higher red light fluences and longer incubation times are associated with longer remission, but also with more pain and local reactions[50] (Fig. 135.7). Currently, there is no consensus as to the optimum PDT parameters for treating acne.

It should be noted that *Cutibacterium* (formerly *Propionibacterium*) *acnes* produces cutaneous porphyrins, which can be readily demonstrated with Wood's lamp examination of any sebaceous-dense area, including normal skin. Exposure to high-intensity blue light alone, in the absence of any exogenous PDT prodrug, can lead to clinical improvement of inflammatory acne lesions.

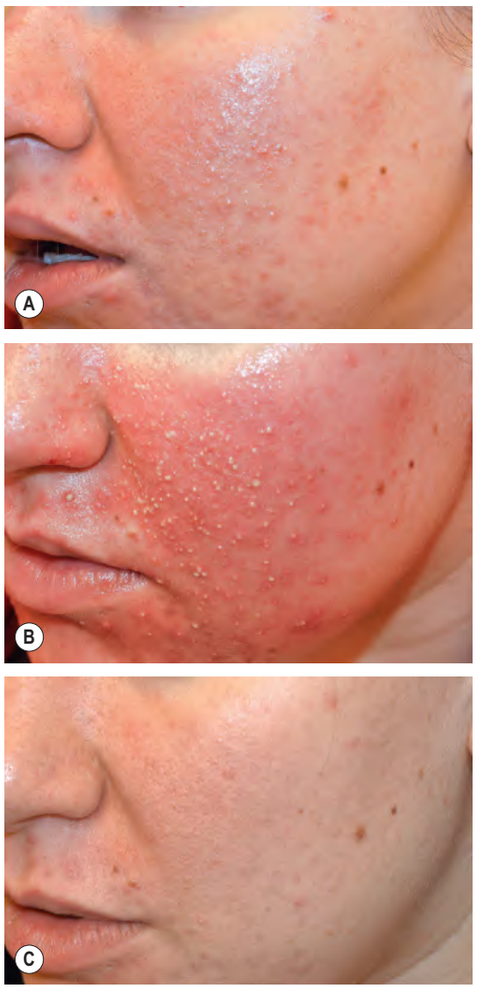

Fig. 135.7 Use of photodynamic therapy (PDT) for moderate but recalcitrant acne vulgaris. This patient declined the use of oral isotretinoin and had failed therapy with topical agents and oral antibiotics. **A** Baseline. **B** Three days after PDT utilizing topical 20% 5-aminolevulinic acid (ALA; 3 hours incubation) followed by irradiation with red light from an LED (light-emitting diode; 630 nm; 37 J/cm^2; 70 mW/cm^2); intense inflammation and pustulation is limited to treated sites. **C** Two months after single treatment session.

PDT has also been used to treat other acneiform disorders. It was superior to topical 1% clindamycin for the treatment of perioral dermatitis in a small split-face trial[51]. Rosacea and hidradenitis suppurativa represent other diseases for which PDT was reported as being useful[52,53]. In patients with rosacea, ALA-PDT reduced papulopustular lesions as well as flushing, pruritus, burning, and prickling sensations.

Photoaging

When used to treat AKs and keratinocyte carcinomas, PDT is thought to produce cosmetically favorable results, including improvement of sun-damaged skin. Well-designed trials directly comparing PDT to non-PDT treatments in which photoaging is the primary focus are sparse relative to the extent that this treatment approach is promoted and used in clinical practice (see Fig. 135.5). A randomized trial of repetitive D-PDT to prevent AKs found a significant reduction in fine lines, pigmentation, skin roughness, and erythema[54]. Optimal PDT parameters for treatment of photoaging have not yet been determined. Histologically, PDT appears to increase collagen deposition and decrease elastosis[55].

Cutaneous infections

There are several mechanisms by which PDT can treat infectious diseases. Singlet oxygen may directly destroy microbes or it may activate host immunologic reactions against the microorganisms. In addition, PDT can induce necrosis of infected tissue, for example, in the treatment of verrucae or condylomata. Conditions that have been shown, in controlled trials, to improve with PDT include verrucae vulgares[56], condylomata acuminata[57], and leishmaniasis[58]. The emergence of drug-resistant bacteria plus the need for better antibiotic stewardship have also motivated investigations into employing PDT for bacterial skin infections and colonized chronic leg ulcers[59]. In addition, PDT has been used on superficial fungal infections such as tinea pedis and onychomycosis.

Vascular anomalies

Systemic photosensitizers are biodistributed via the peripheral circulation and it stands to reason that intravascular drug activation with light would be useful in inducing the involution of abnormal vascular structures. Vascular malformations such as port-wine birthmarks have been shown to respond to systemic PDT with results that appear to be at least equivalent to those achieved with conventional pulsed dye laser therapy[60]. Experience with this technique is largely from China, where hematoporphyrin-type preparations are used systemically. Topical ALA/pulsed dye laser-activated PDT has also been described[61], taking advantage of combined photodynamic and photothermal effects.

ADVERSE EFFECTS AND COMPLICATIONS OF PDT

Neither PDT photosensitizers nor artificial visible light ordinarily possess significant inherent toxicity, and the adverse effects related to PDT are largely an extension of the photochemical and photobiologic reactions that are generated by reactive oxygen moieties. Interestingly, erythropoietic protoporphyria and X-linked dominant protoporphyria could be considered possible toxicity models for ALA and its congeners since they result in constitutive overaccumulation of PpIX.

Photosensitivity

With topical PDT, photosensitivity manifests as varying degrees of local erythema, edema, and/or blistering of any exposed site, with subjective symptoms of pain or a burning sensation. Conventional chemical sunscreens, even those with a high sun protection factor, are not useful in managing local photosensitivity since the action spectrum extends throughout the visible spectrum, which is not blocked by these sunscreens.

Pain

The incubation period, which follows application of the topical photosensitizer, is generally uneventful, but within seconds to minutes of illumination of the skin with artificial light, patients will often experience a range and series of unpleasant sensations at the site of light exposure. Various terms are relayed by patients to describe these sensations, including pain, warmth, burning, stinging, smarting, and

Downloaded for Anonymous User (n/a) at Egyptian Knowledge Bank from ClinicalKey.com by Elsevier on March 10, 2024. For personal use only. No other uses without permission. Copyright ©2024. Elsevier Inc. All rights reserved.

stabbing. The intensity will usually build with time and there can be spread of the discomfort beyond the actual treatment field. Studies of factors associated with this pain have found inconsistent associations, including older age, treatment of AKs or well-innervated areas like the face and scalp, size of the treatment area, skin phototypes I–II, use of ALA as the photosensitizer, and intensity of ALA-induced fluorescence[62].

The rate of light delivery can influence the degree of pain, with lower irradiances being more tolerable[15]. In D-PDT, a lower irradiance is used for photosensitizer activation and this technique is associated with significantly less pain[3]. Other potential strategies for modifying irradiance include increasing the distance from the light source and the use of low-irradiance, portable LED sources[10,11]. Sometimes, temporary interruption of the artificial light exposure will allow the pain to dissipate temporarily.

A variety of practical strategies have been designed to manage the pain of PDT (Table 135.5). Of note, topical anesthesia with eutectic

STEPS IN ADMINISTERING TOPICAL PHOTODYNAMIC THERAPY AND PRACTICAL CONSIDERATIONS
Preoperative phase

• Confirm that the patient is a good candidate for PDT: appropriate indication, assess comorbidities; consider PDT especially in the setting of:
  • Field cancerization
  • Multiple synchronous or metachronous superficial tumors
  • Skin cancer-prone genodermatosis
  • Solid organ transplant recipient
• Select treatment site(s) and confirm diagnosis by histologic examination if necessary
• Exclude contraindications: porphyria, photosensitivity disorder, pregnancy, photosensitizer hypersensitivity
• Provide patient with counseling and education in terms of expectations and precautions
• Determine the photosensitizer, light source, and treatment parameters that will be employed
• Determine the number of PDT sessions to be given, the number of light exposures per session (fractionation), and the time interval; for keratinocyte carcinomas, two separate PDT sessions one week apart are recommended
• Check weather report (temperature, precipitation) if daylight-activating PDT is to be used

Intraoperative phase
Topical drug application
• Confirm treatment site(s) • Consider degreasing the treatment surface with topical acetone or by microdermabrasion • Apply chemical sunscreen to all exposed skin (daylight-activating PDT only) • Prepare treatment site(s): most commonly by gentle curettage of excess stratum corneum or scale-crust if appropriate; consider using microneedling or fractional laser • Apply topical photosensitizer to the target treatment site(s); occlusion and coverage by opaque material are optional • Incubate the photosensitizer according to the indication, specific prodrug, and light source to be used
Light administration/drug activation

• Non-coherent artificial light activation
  • Remove any residual topical medication prior to light exposure
  • Confirm the presence of PpIX fluorescence by Wood's lamp examination (optional)
  • Provide protective eyewear to patient and staff
  • Position patient and lamp(s) for uniform exposure and patient comfort
  • Confirm light dose to be given, and then initiate light exposure (typically 5–15 minutes depending on the light source); a healthcare professional can assist with pain management during the light exposure if necessary (see below)
• Daylight (outdoor) activation
  • Confirm the field area to be exposed to daylight
  • Provide timer and monitor treatment duration during light exposure (~2 hours)
  • Periodically verify tolerance of treatment with patient
  • Cleanse treatment area upon return to the clinic to remove any residual topical photosensitizer
• At the completion of the light exposure, confirm photobleaching of PpIX by Wood's lamp examination (optional)

Pain management during light exposure

• Assemble tools and devices for pain control
• The physical presence of a healthcare professional is very important for providing reassurance and monitoring; verbal reassurance and distraction, especially during artificial light-activated PDT
• Reinforce to the patient that the sensation of pain indicates that the appropriate PDT reactions are occurring
• Additional specific strategies for managing pain may include:
  • Applying an ice cube or ice pack near the treatment site
  • Spraying cold water over the treatment site
  • Providing a fan that can be held by the patient
  • Directing forced cold air toward the treatment site
  • Interrupting the light exposure temporarily
  • Infiltration, nerve block, or tumescent local anesthesia
  • Hypnosis
  • Nitrous oxide/oxygen mixture inhalation
  • Transcutaneous nerve stimulation

Postoperative phase
• Reduce swelling by using ice packs • Prescribe oral analgesics to be taken if necessary • Recommend avoidance of sun exposure and bright indoor light for 48 hours • Arrange follow-up, including next PDT session if appropriate; for keratinocyte carcinomas, a repeat course/cycle of PDT may be appropriate 2–3 months after the first course/cycle if there is clinical evidence of residual disease • If lesion recurs despite multiple treatment cycles, consider alternate treatment (e.g. surgery, radiotherapy)

Table 135.5 Steps in administering topical photodynamic therapy (PDT) and practical considerations. ALA, 5-aminolevulinic acid; LED, light-emitting diode; mALA, methyl aminolevulinate; PpIX, protoporphyrin IX.

Downloaded for Anonymous User (n/a) at Egyptian Knowledge Bank from ClinicalKey.com by Elsevier on March 10, 2024. For personal use only. No other uses without permission. Copyright ©2024. Elsevier Inc. All rights reserved.

mixture of lidocaine 2.5% and prilocaine 2.5% (EMLA®), morphine gel, tetracaine gel, or capsaicin cream is generally ineffective. Moreover, in one trial, there was no difference between placebo and oxycodone plus acetaminophen in time to pain onset and level of pain[63]. Scalp nerve blocks appear superior to intravenous analgesics and forced cold air[64]. For some patients, the pain can be so intense that they will not be willing to undergo any more than one treatment session.

Inflammation

At the end of the light exposure, the treated site will usually exhibit an immediate wheal and flare reaction. Over the next 24–48 hours, localized phototoxicity may manifest as edema, induration, urticaria, purpura, pustules, and blistering, along with exudation and crusting (Fig. 135.8). Depending on the indication and the PDT drug–light dose, frank tissue necrosis may supervene accompanied by erosions and ulceration. Local reactions can evolve over the ensuing 1–4 weeks and any wounds will heal by second intention.

For the treatment of AKs, cutaneous application of mALA for 30 minutes (rather than the recommended 3 hours) and/or pretreatment with superpotent topical corticosteroids led to reduced cutaneous inflammation but equivalent efficacy[65]. D-PDT typically generates local reactions that are milder and of shorter duration.

Fig. 135.8 Erythema, edema, and multiple pustules 4 days after photodynamic therapy (PDT) for actinic keratoses. Topical 20% 5-aminolevulinic acid (ALA) was followed by irradiation with red light from an LED (light-emitting diode).

Photosensitizer Allergy

Multiple case reports have documented contact hypersensitivity to mALA. In a controlled trial, contact sensitization to mALA was observed in as many as 35% of patients who had *previously* undergone five or more mALA-based PDT sessions; only 1.7% of the control subjects who had not previously undergone PDT demonstrated sensitization[66].

Rare, Unusual or Controversial Reactions

Exceptionally, PDT has been reported to precipitate herpes simplex reactivation[67], facial nerve palsy, hypertensive crisis, alopecia, localized bullous pemphigoid, pityriasis rubra pilaris, erosive pustular dermatosis of the scalp, and transient memory impairment. Cases of keratinocyte carcinomas recurring with more aggressive histology[68], arising *de novo*[69], or progressing within PDT fields have been reported; melanomas have also been reported following PDT, but the significance of these findings is difficult to interpret in the absence of control data.

PRACTICE AND TECHNIQUES

The practical administration of PDT requires attention to a number of details during the preoperative, intraoperative, and postoperative stages (see Table 135.5). Although the commercial PDT systems for dermatology come with officially recommended and approved protocols, the practice of PDT is not uncommonly off-label, both in terms of indications and specific procedural steps guided by the individual practitioner's experience and empiric preferences. One round of topical drug plus light (administered as a single exposure or as multiple fractionated exposures) can be considered a single PDT session. A "course" or "cycle" of PDT may involve one or more individual PDT sessions separated by a set time interval. What should not be underestimated is the time and staffing necessary to provide appropriate patient counseling and education as well as intraoperative support and supervision during the light exposure phase. Consensus recommendations and guidelines from various expert groups and dermatologic societies have been published to guide the use of PDT[13,70,71].

FUTURE DIRECTIONS

Controlled trials and cumulative clinical experience continue to redefine the spectrum of PDT applications. On the horizon are new photosensitizers and novel ways of delivering ALA. Knowledge gained from D-PDT, including less associated pain, has led to investigations in which low irradiance LED sources are used instead of conventional light sources. Advances in PDT have been accompanied by progress in imaging techniques such as confocal reflectance microscopy. Combination of the two in the future could lead to noninvasive diagnosis and delineation of cutaneous carcinomas as well as treatment and long-term evaluation.

Additional figures available in our eBook (see inside front cover for access code).

expedited microneedle-assisted photodynamic therapy II clinical study evaluating the noninferiority of a new Light fractionation significantly improves the response

Downloaded for Anonymous User (n/a) at Egyptian Knowledge Bank from ClinicalKey.com by Elsevier on March 10, 2024. For personal use only. No other uses without permission. Copyright ©2024. Elsevier Inc. All rights reserved.

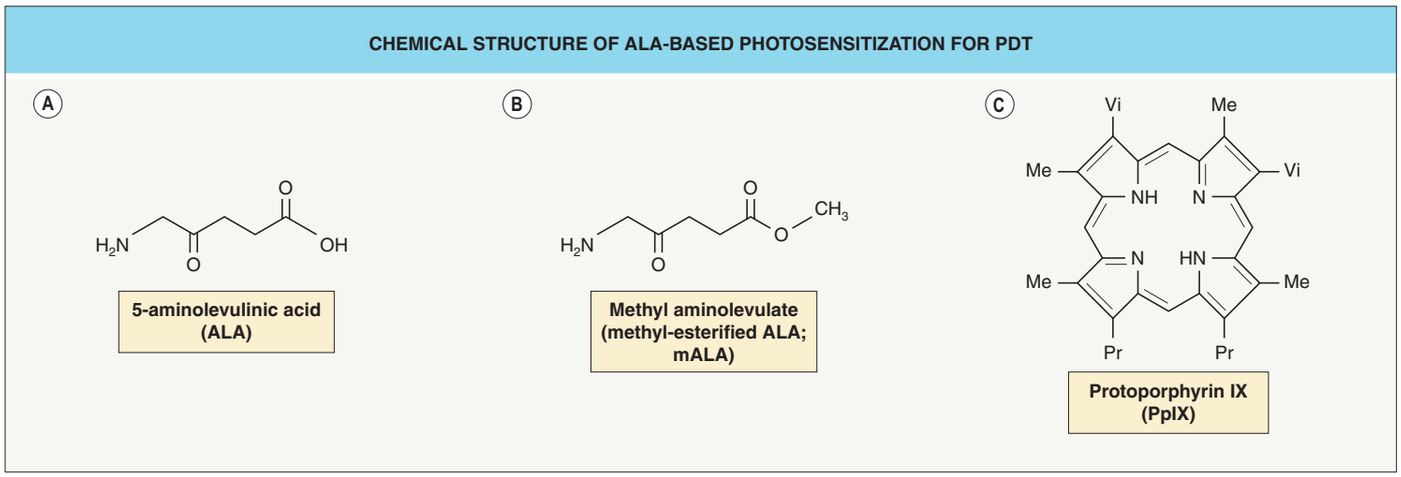

eFig. 135.1 Chemical structure of ALA-based photosensitization for PDT. A 5-aminolevulinic acid (ALA). **B** Methyl aminolevulinate (methyl-esterified ALA; mALA). **C** Protoporphyrin IX (PpIX). Me, methyl; Pr, propionic acid; Vi, vinyl.

eFig. 135.2 Photodynamic therapy (PDT) of facial actinic keratoses. A Pre-treatment. **B** Three months following PDT utilizing topical methyl aminolevulinate (mALA; 3 hours under occlusion) plus irradiation with red light from an LED (light-emitting diode), resulting in clearing of lesions.

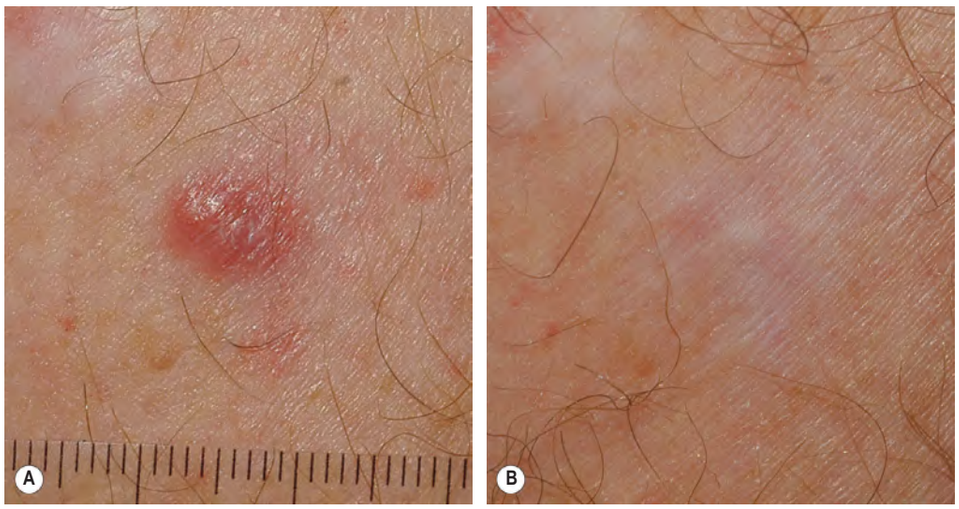

eFig. 135.3 Photodynamic therapy (PDT) of a superficial basal cell carcinoma (BCC). A Superficial BCC prior to treatment. **B** Two years following PDT utilizing topical methyl aminolevulinate (mALA; 3 hours under occlusion) plus irradiation with red light from an LED (light-emitting diode; 37 J/cm^2), with complete clinical resolution.

Downloaded for Anonymous User (n/a) at Egyptian Knowledge Bank from ClinicalKey.com by Elsevier on March 10, 2024. For personal use only. No other uses without permission. Copyright ©2024. Elsevier Inc. All rights reserved.

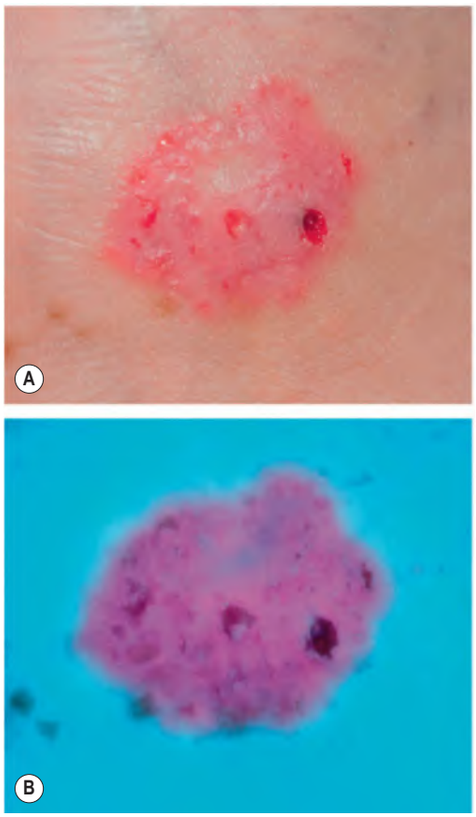

eFig. 135.4 Fluorescence of intratumor protoporphyrin IX (PpIX) when illuminated by a Wood's lamp (365 nm). A Superficial basal cell carcinoma (BCC). **B** Following application of topical methyl aminolevulinate (mALA) for 3 hours under occlusion, the BCC demonstrates selective pink–red fluorescence due to accumulation of PpIX.

Downloaded for Anonymous User (n/a) at Egyptian Knowledge Bank from ClinicalKey.com by Elsevier on March 10, 2024. For personal use only. No other uses without permission. Copyright ©2024. Elsevier Inc. All rights reserved.